



Patella fracture after TKA

Professeur Sébastien LUSTIG

Groupement Hospitalier Nord - Université Lyon 1,

LYON - FRANCE

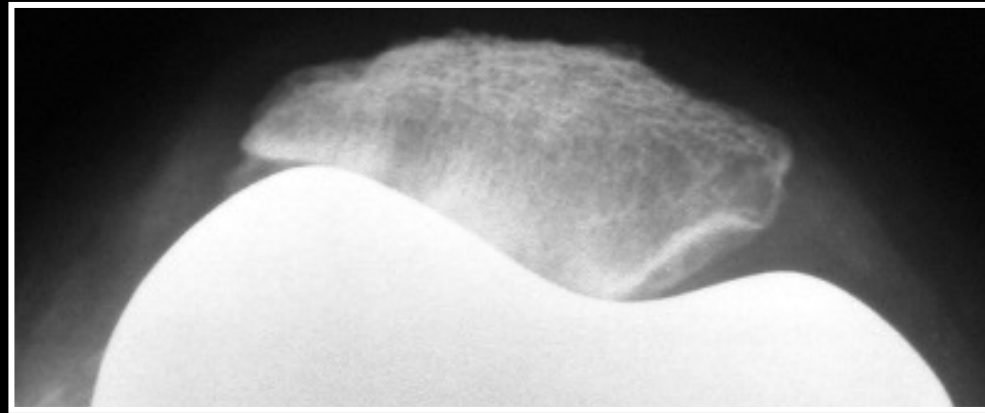
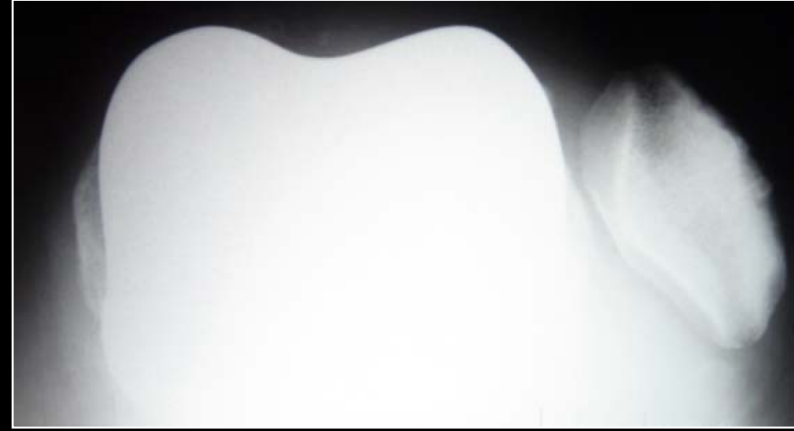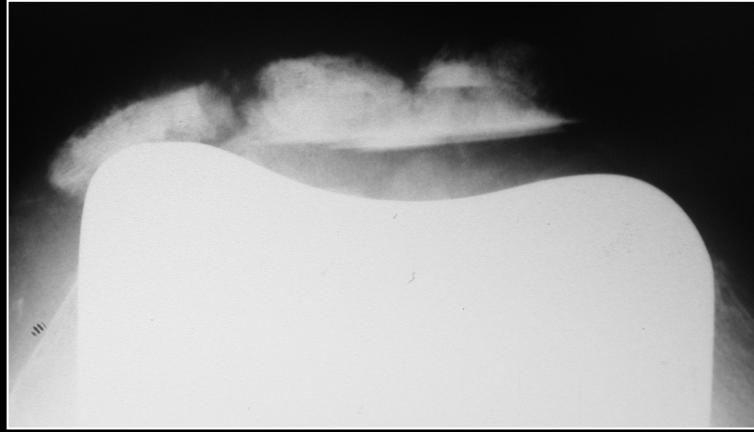
Université Claude Bernard



Lyon 1



Hospices Civils de Lyon

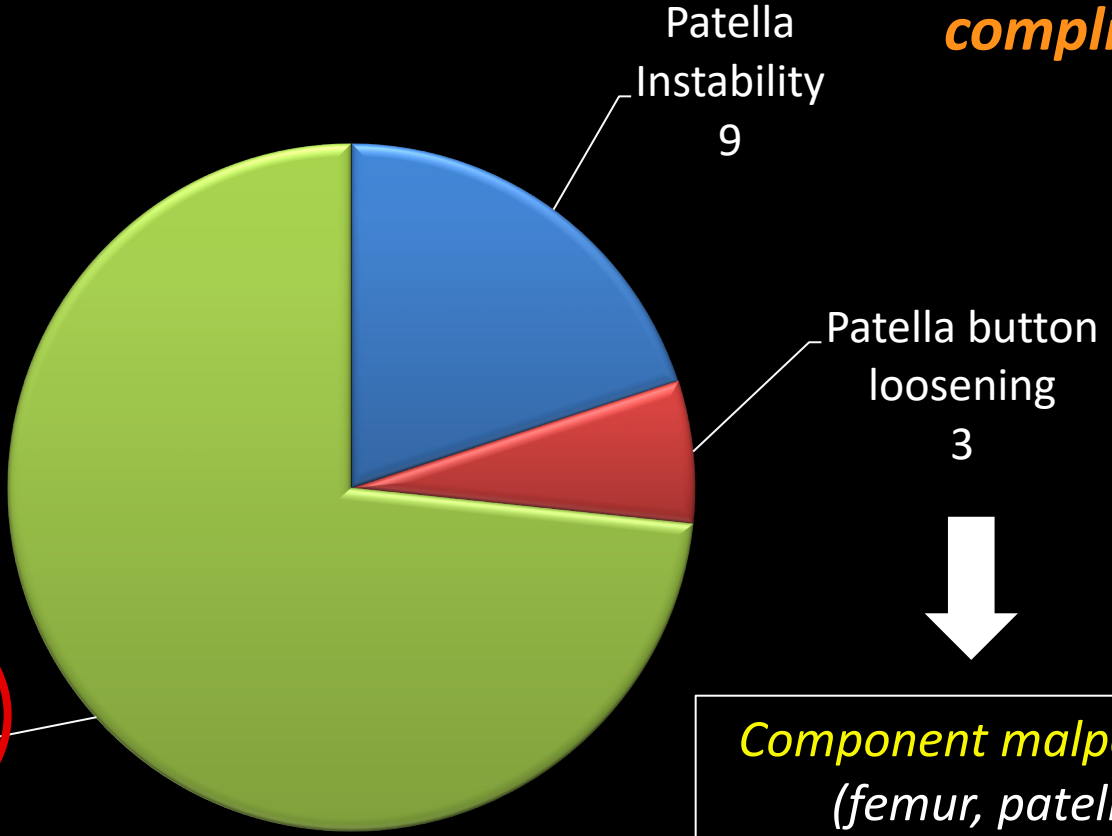
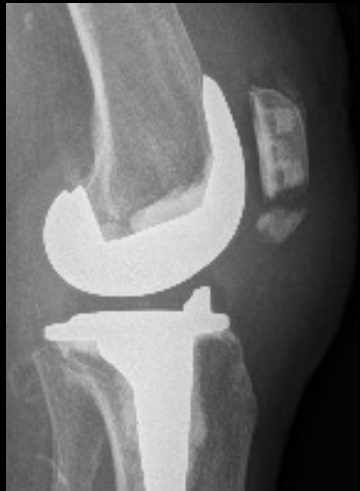

Is it frequent ?

1.1 %
(except Clunk syndrome)

4014 TKA 3rd condyle

Patella complication

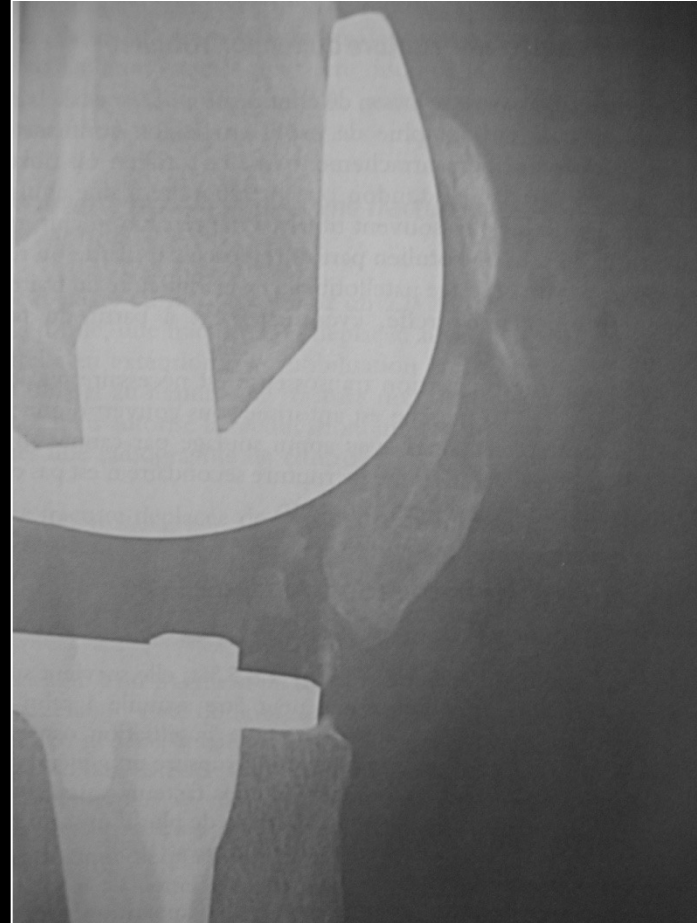

Patella fracture
33

↓
Component malpositionning
(femur, patella +++)

Diagnosis ?

- Treatment ?
- No specificity of clinical symptoms



1. CT Scan

2. Bone scan

Risk factors

- BMI > 30 kg/m²
- Male
- Varus > 5°
- Large patella button

Meding et al

Corr 2008;466(11):Predicting patellar failure after total knee arthroplasty

Treatment

- Abstention (vertical fracture, no extension lag)
- ORIF
- Partial patellectomy
- Ext mechanism allograft

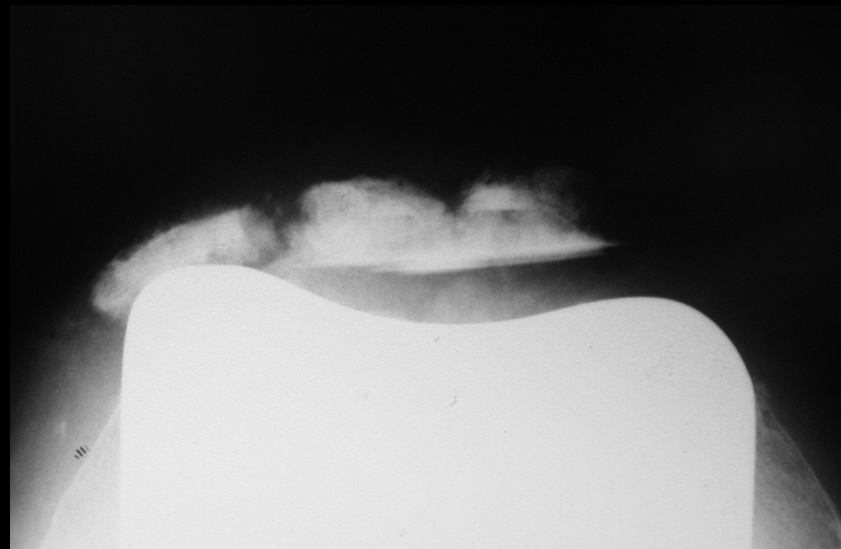
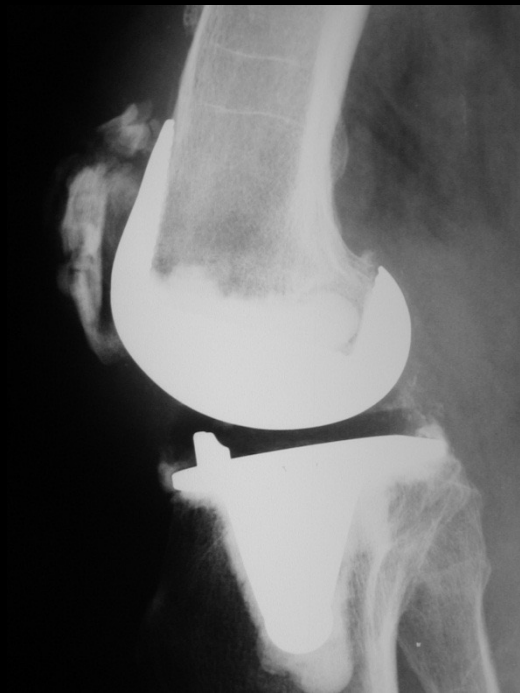
Case1

- H 74 ys,

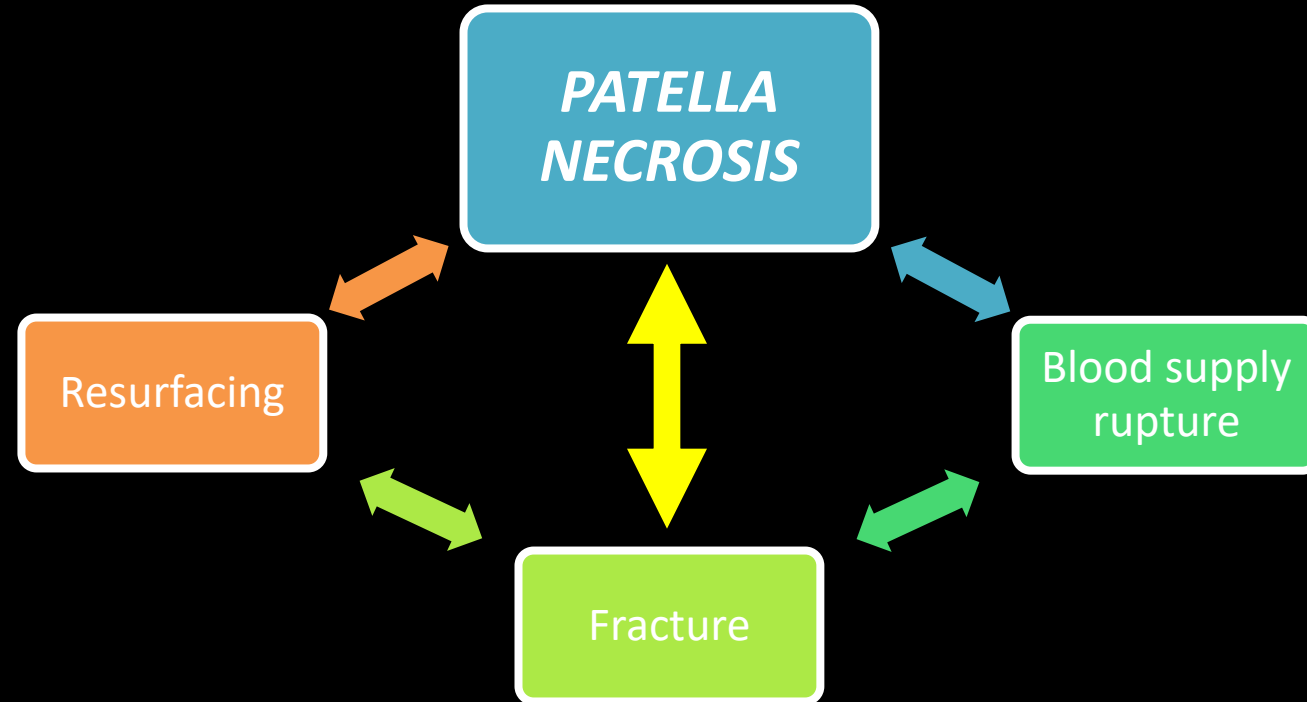
TKA for SPONK

6 month FU : acute knee pain walking down stairs

Case1



MULTI-FACTORIAL ORIGIN



- **Blood supply rupture:**

- Medial approach +++

- *Blood supply to the patella. Significance in total knee arthroplasty, Brick et al.*

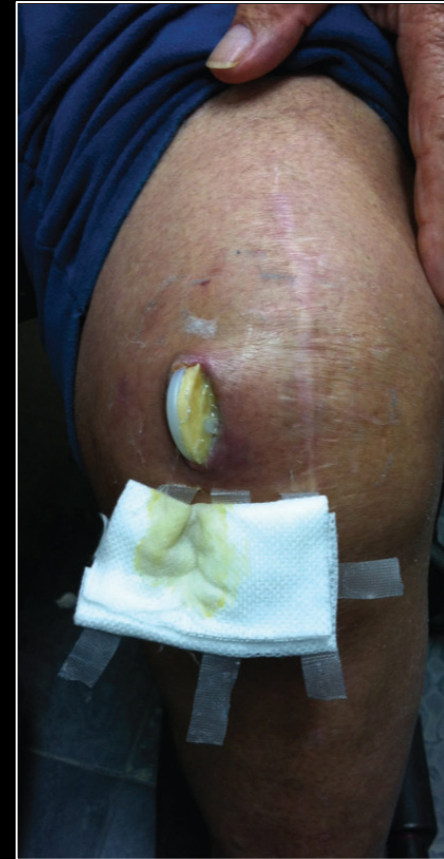- Lateral release

- *The relationship of lateral releases to patella viability in total knee arthroplasty, Scuderi et al.*

- Previous scar +++

- **Skin necrosis association +++**

- **Rare**
 - *Osteonecrosis of the patella and prosthetic extrusion after total knee arthroplasty, Noorpuri et al.*




- **Bone resection : resurfacing**

- Admitted as a risk factor of osteonecrosis
+++

- **BUT:**

- Radiolucent zone of the patella following total knee arthroplasty without patellar resurfacing,
Takahashi et al.



LATERAL
FACETECTOMY
???

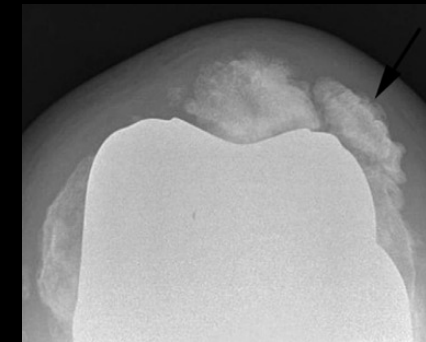
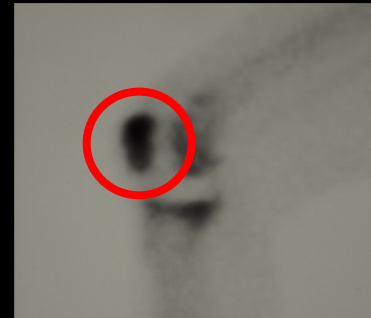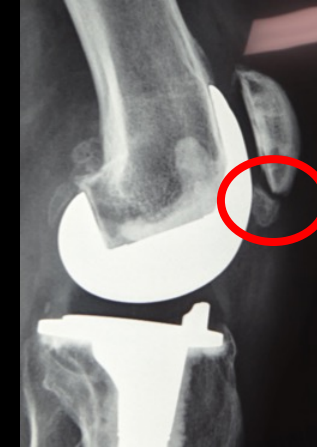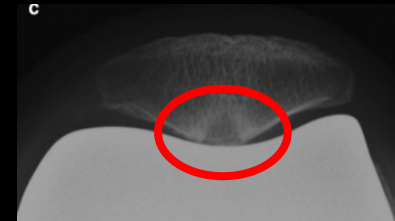PATELLA DENERVATION
???

- **Fractures :**

- Patellar fractures in total knee arthroplasty, [Windsor et al.](#)
 - Stress fracture of the patella following duopatellar total knee arthroplasty with patellar resurfacing, [Scott et al.](#)

DIAGNOSIS

- **Aspecific anterior knee pain +++**
 - Inflammatory knee + effusion
- **X-Ray:**
 - Non traumatic patella fracture
 - Radiolucent zone of the patella
 - **Patella osteolysis +++**
- **TEP: intense hyperfixation**



PREVENTION ?

- **Previous scar management +++**
 - Imperatively use previous scar
 - No bilateral arthrotomy
- **Lateral approach for valgus knee**
 - Collateral ligament balance
 - **Promote patellar tracking**

**DISCUSS NON
RESURFACING +++**

- Previous knee approach
- Thin patella (avoiding fracture +++)

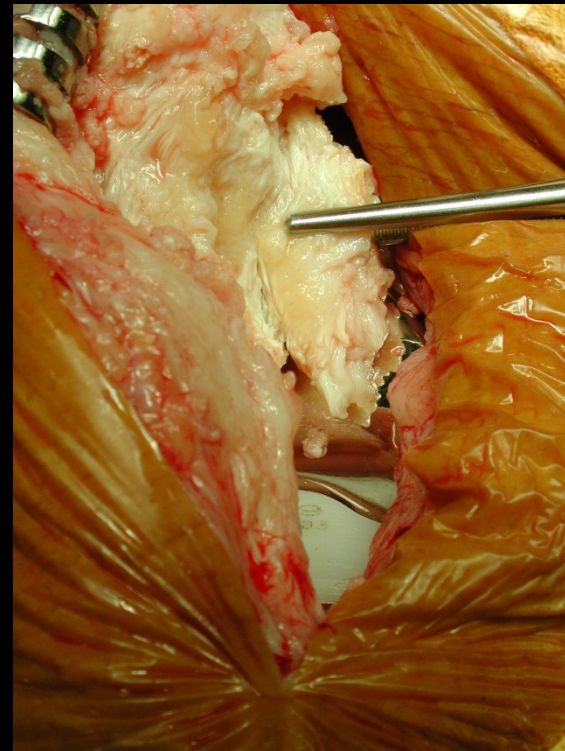
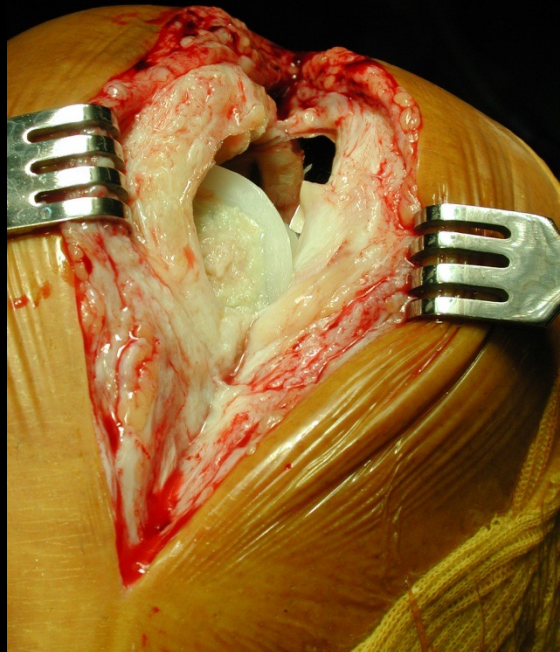
MANAGEMENT

- **No metallic osteosynthesis**
 - *Septic risk +++*
 - Discuss wire osteosynthesis
- Discuss palliative treatment:
 - Total patellectomy ? Partial patellectomy ?
 - Necrosis zone removal +/- cement removal ?
- If no pain and no extension lag : **NONE**

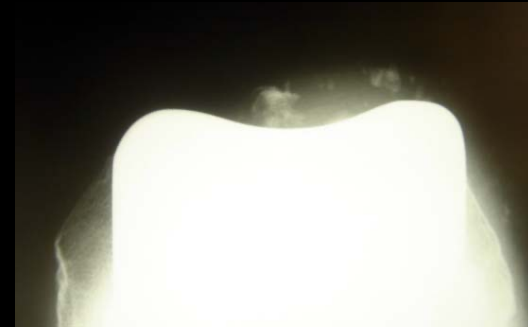
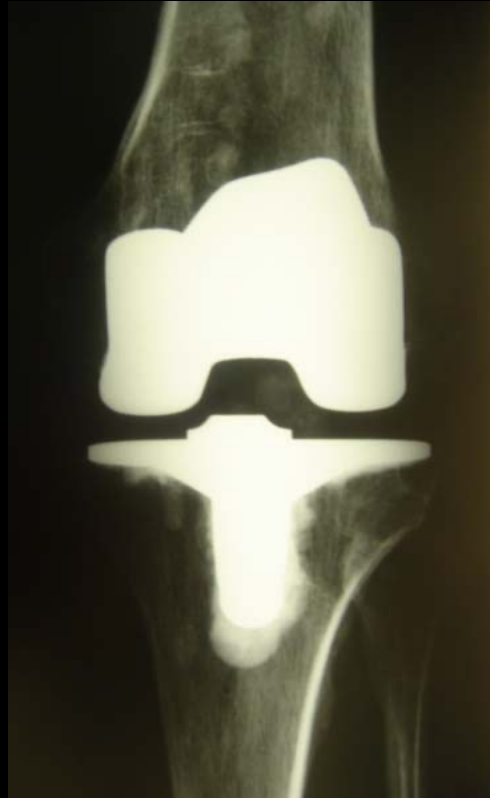
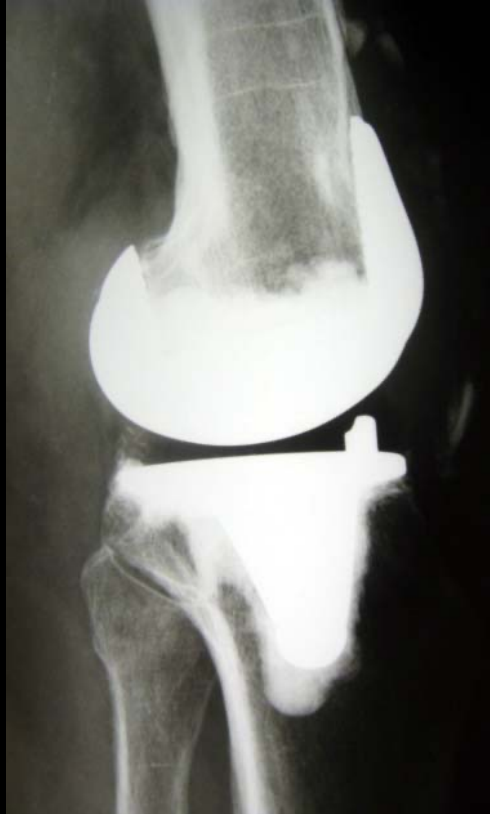
Case 1

- Patella Button loosening: ablation
- Comminutive fracture : patellectomy



Case 1

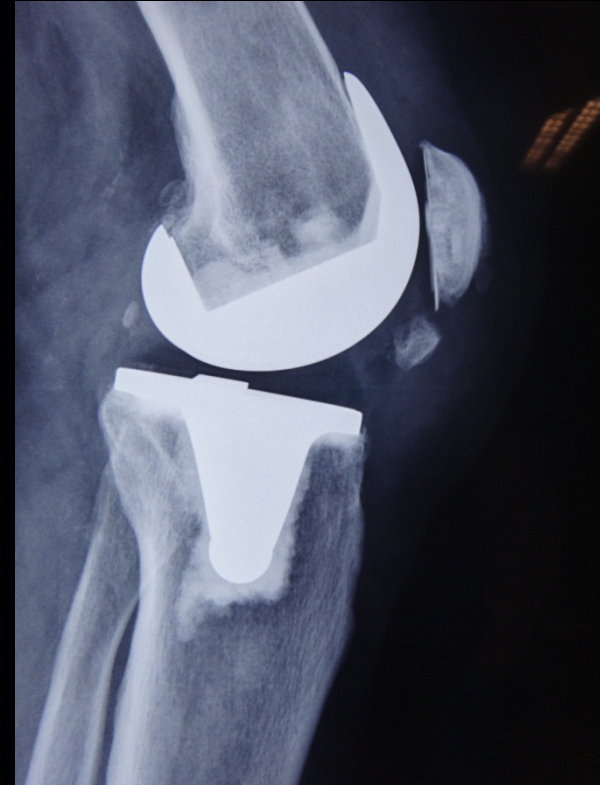

Case 1



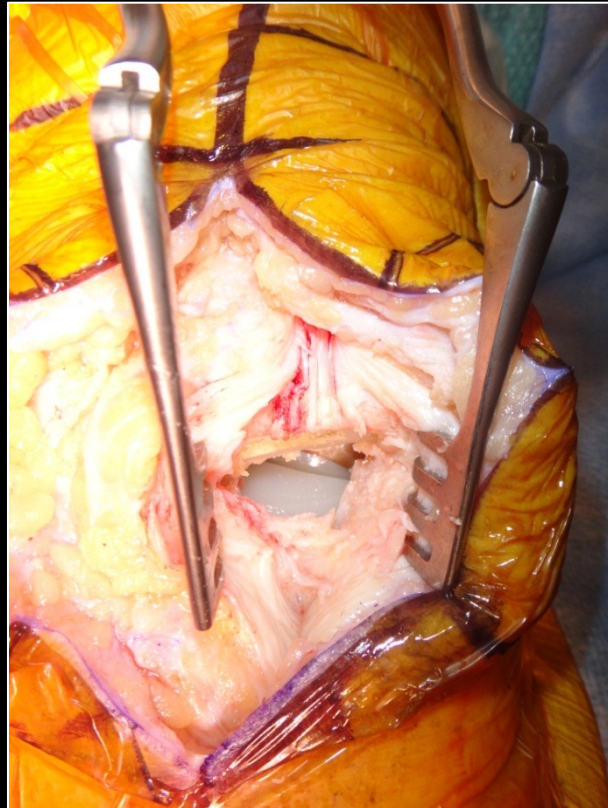
Case2

- H 63 ys GG
- 2008 : TKA
- 2009 : distal fracture of patella
- 2010 : localized pain
- No extension lag



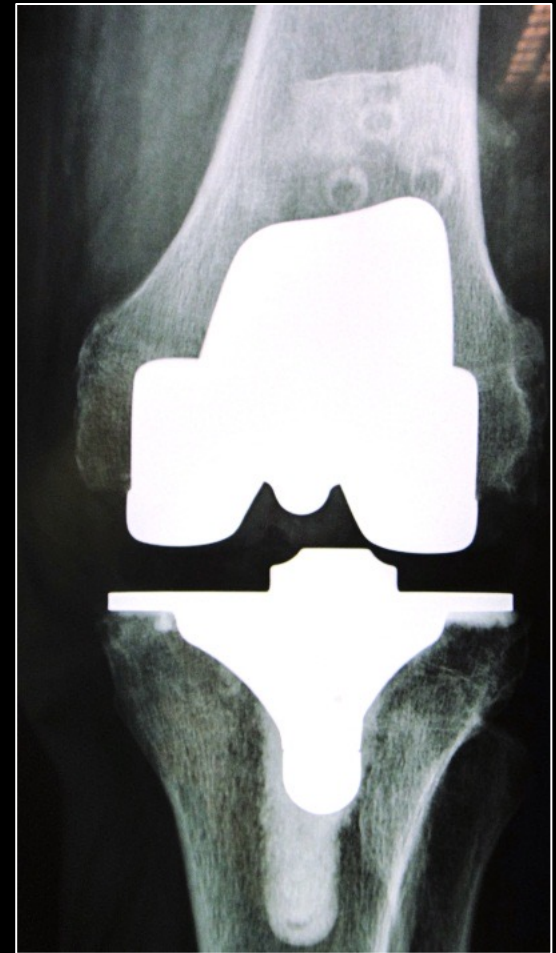
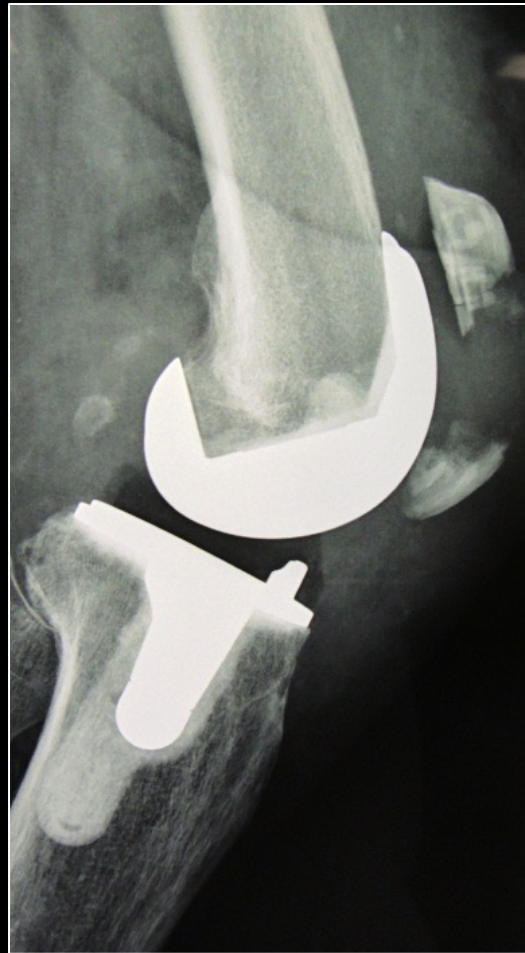Case 2

Bone block removal



Case 3

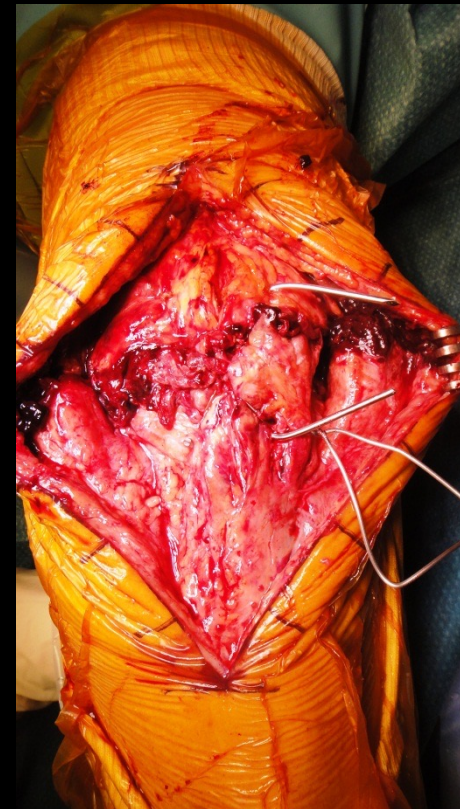
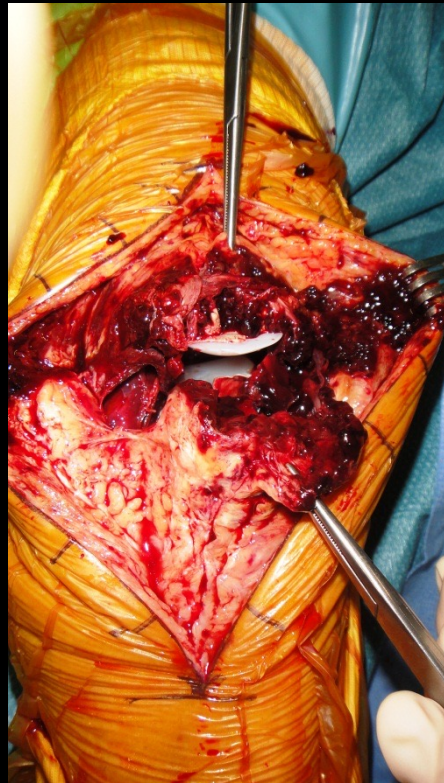- H 80 ys
- Fall in stairs



Case 3

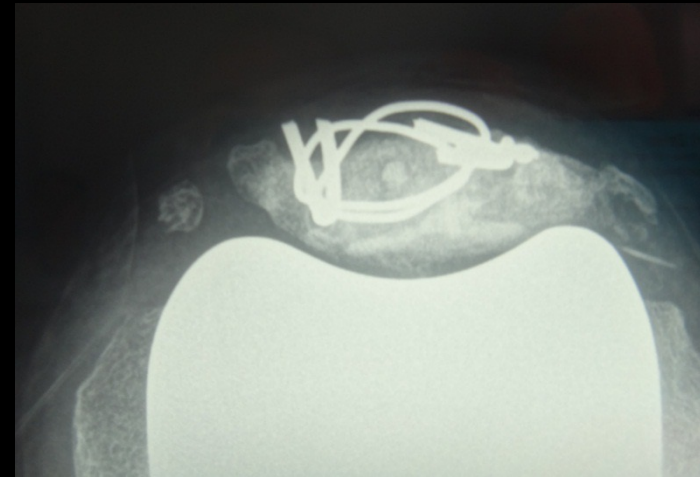
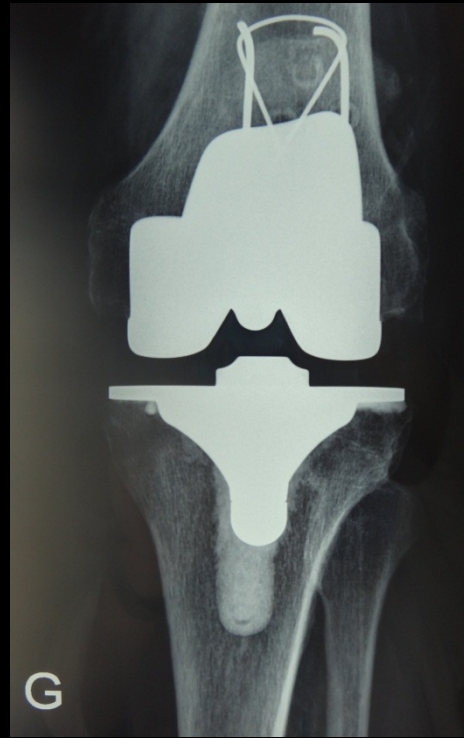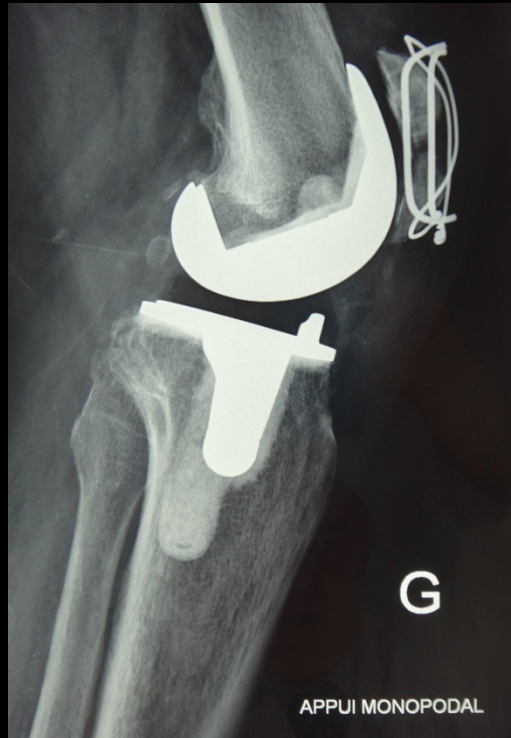Extension lag

ORIF



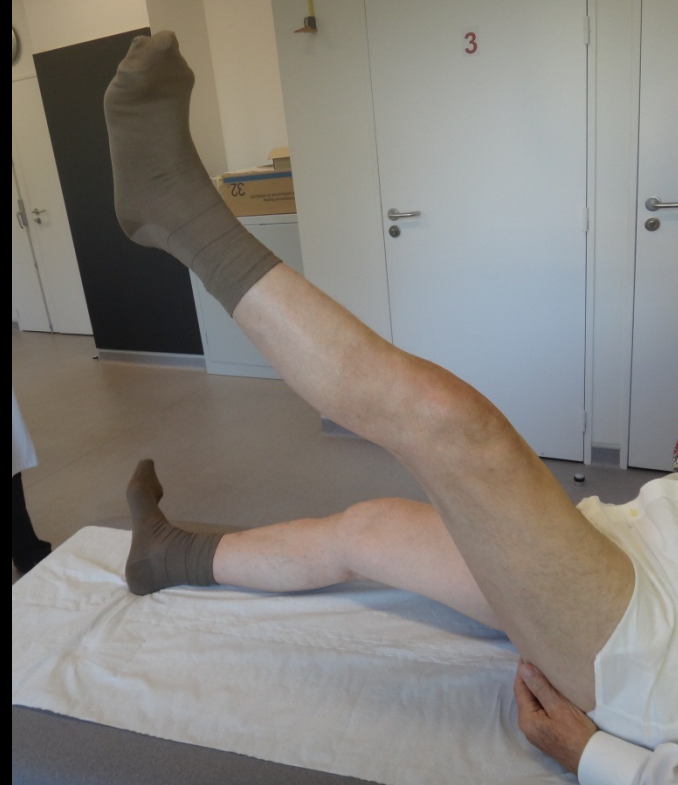Case3

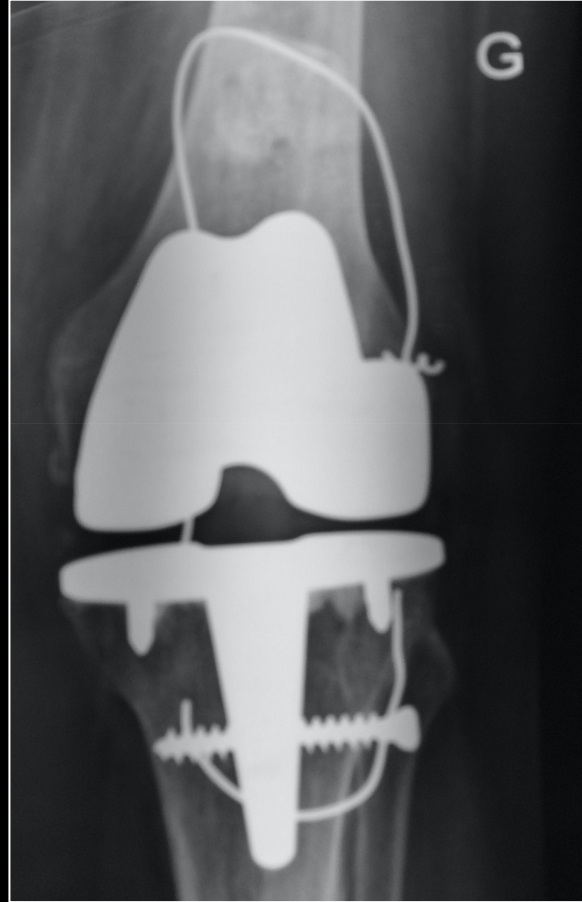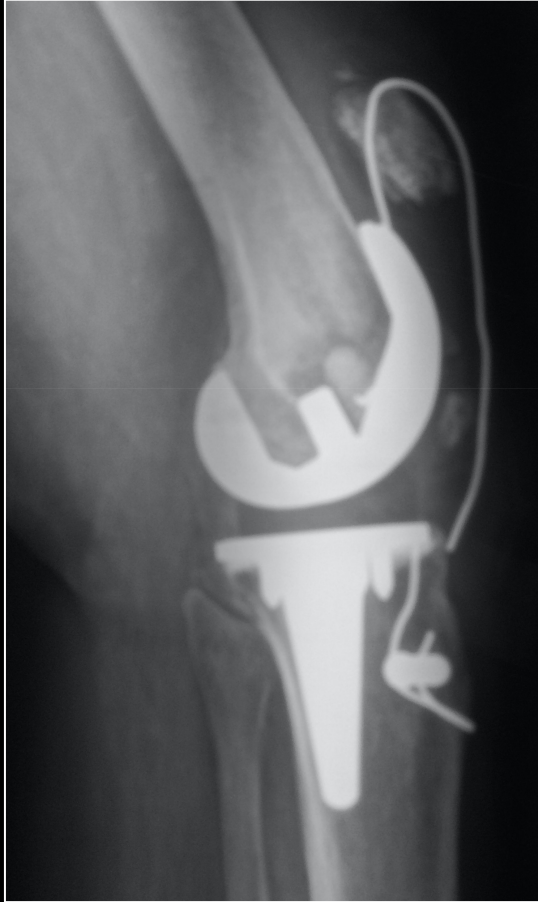2months FU



Case 3

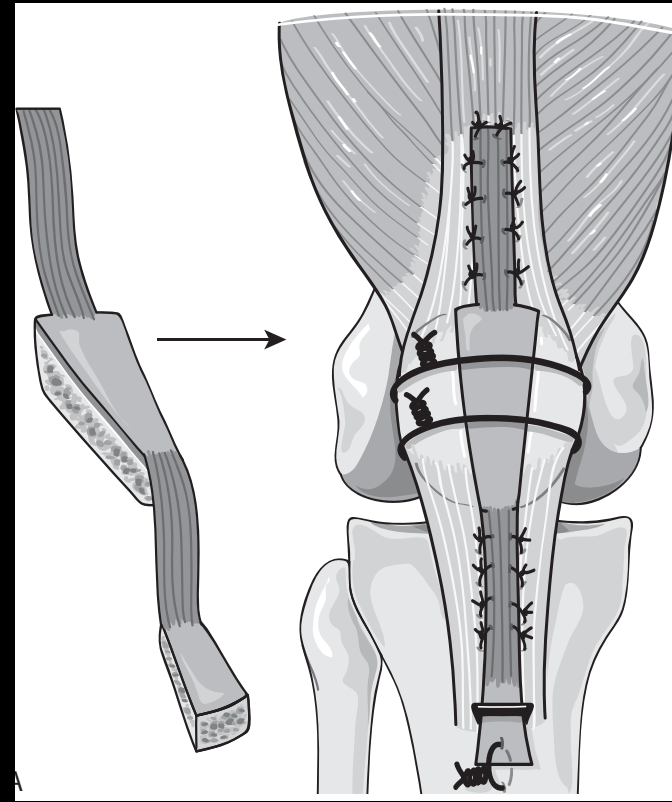
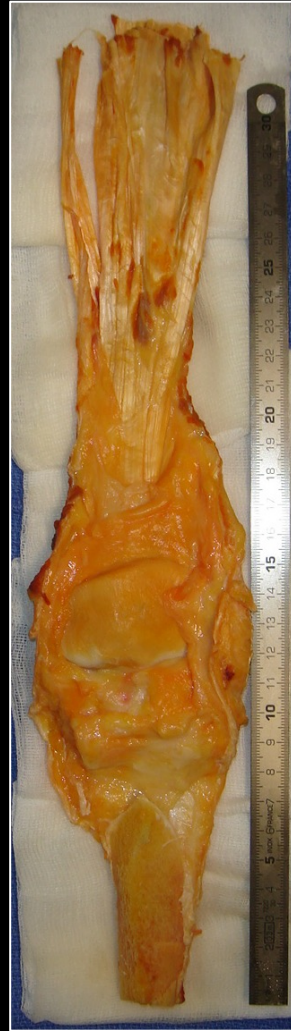- No extension lag

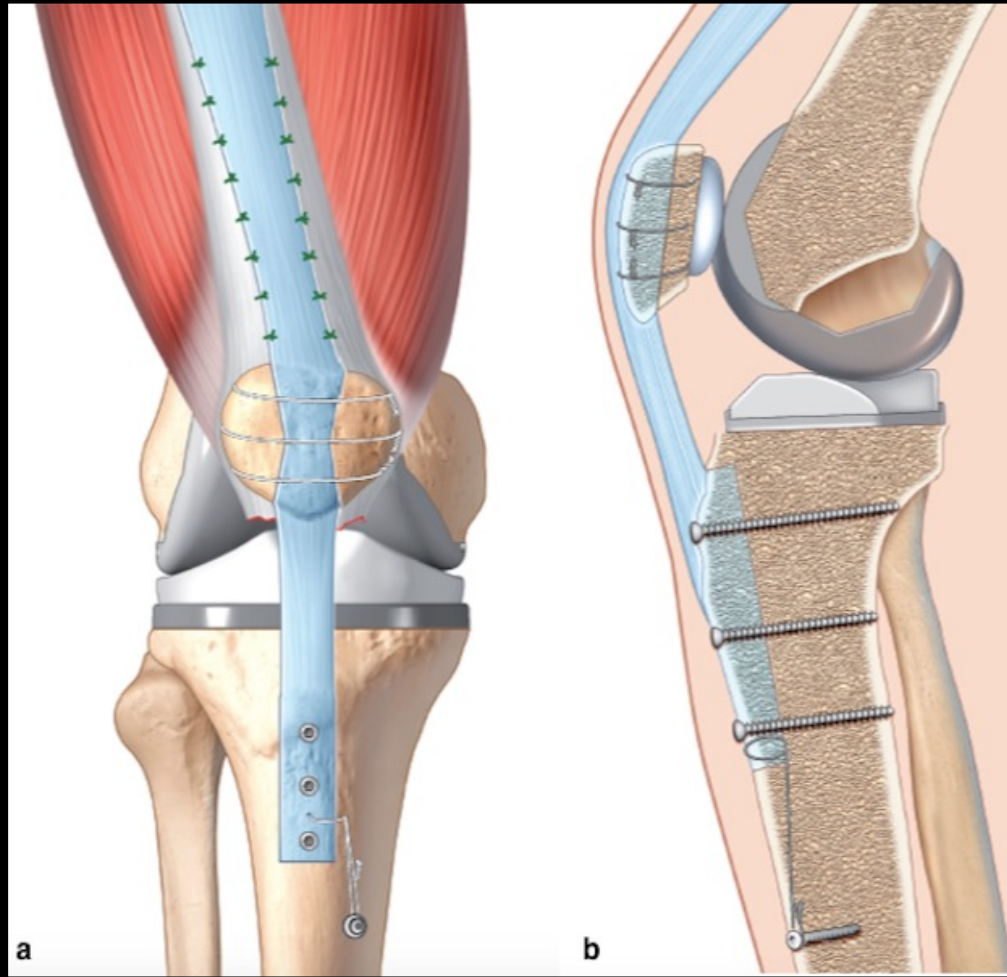




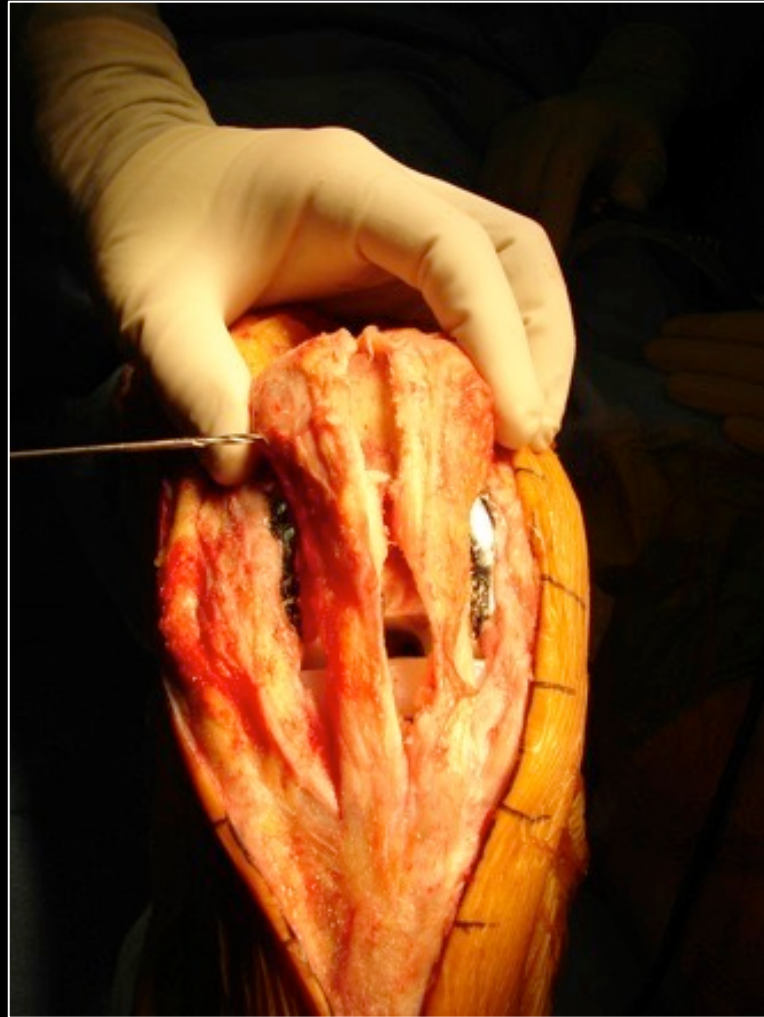
Preoperative sizing +++ on x-rays according to the contralateral knee

Other option : allograft



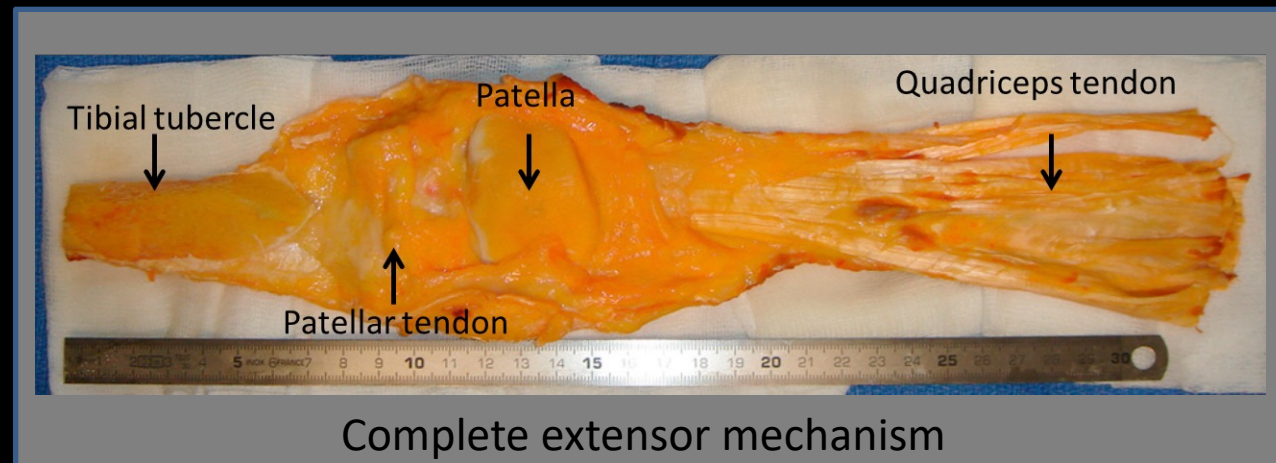


« challenging » situation ...



Surgical procedure

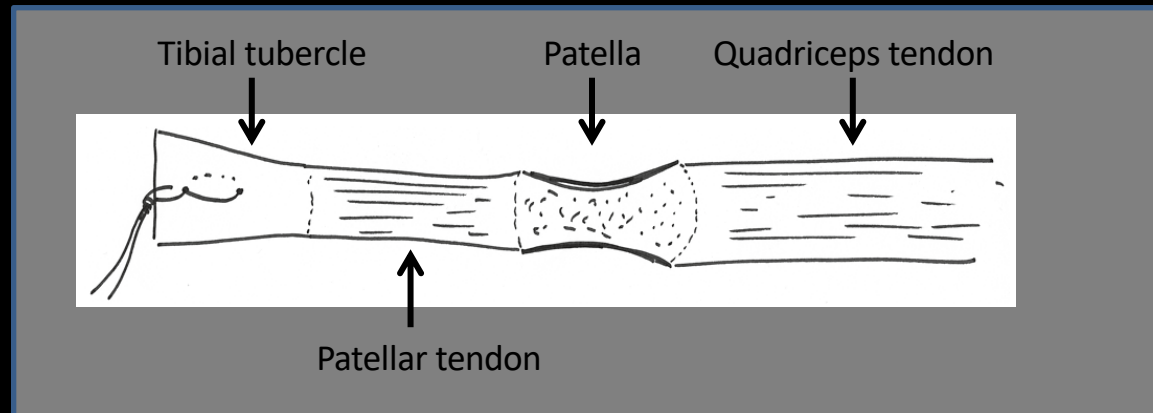
1. Graft : extensor mechanism allograft



← Preoperative sizing +++ on x-rays according to the contralateral knee →

Surgical procedure

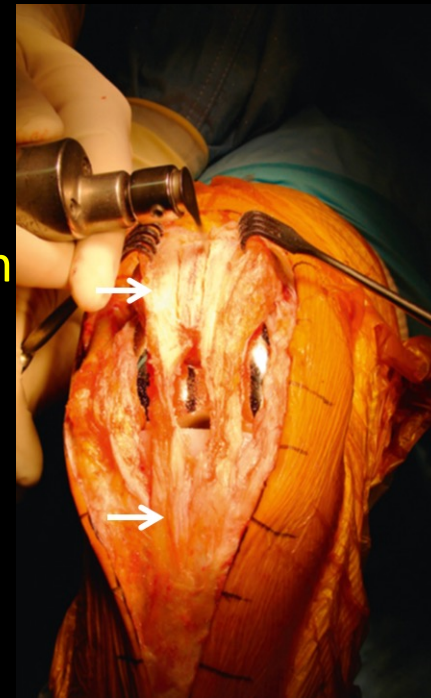
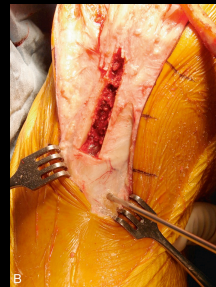
1. Graft : extensor mechanism allograft
2. Preparation of the allograft



Surgical procedure

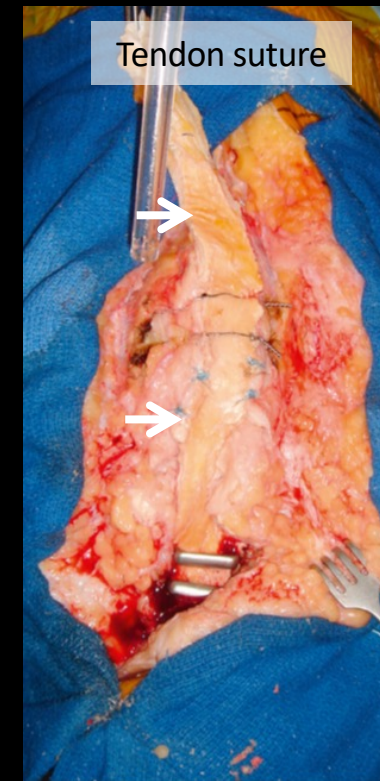
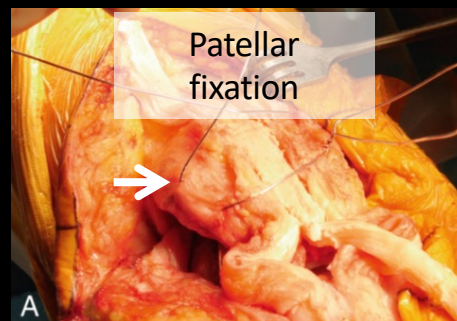
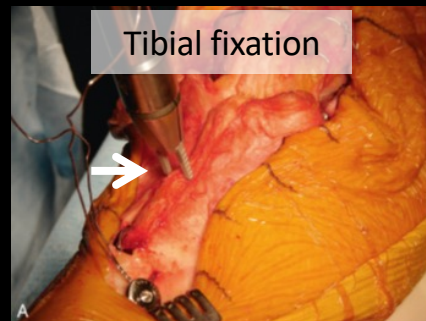
1. Graft : extensor mechanism allograft
2. Preparation of the allograft
- 3. Preparation of the extensor mechanism**

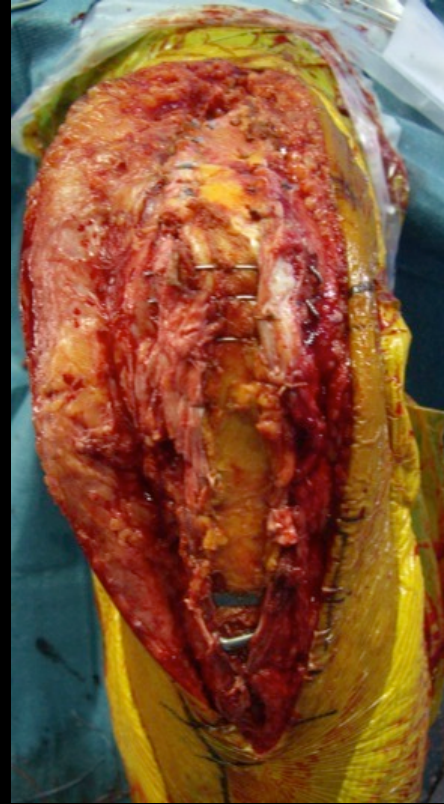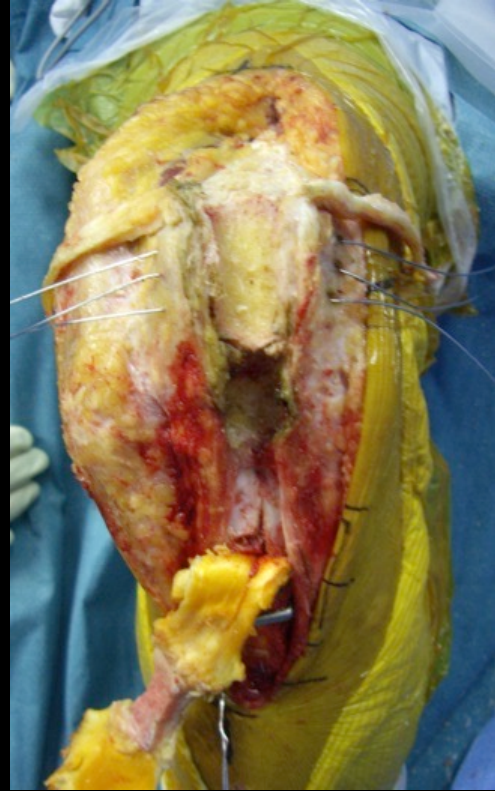2 channels at the anterior part of the patella and tibial tubercle

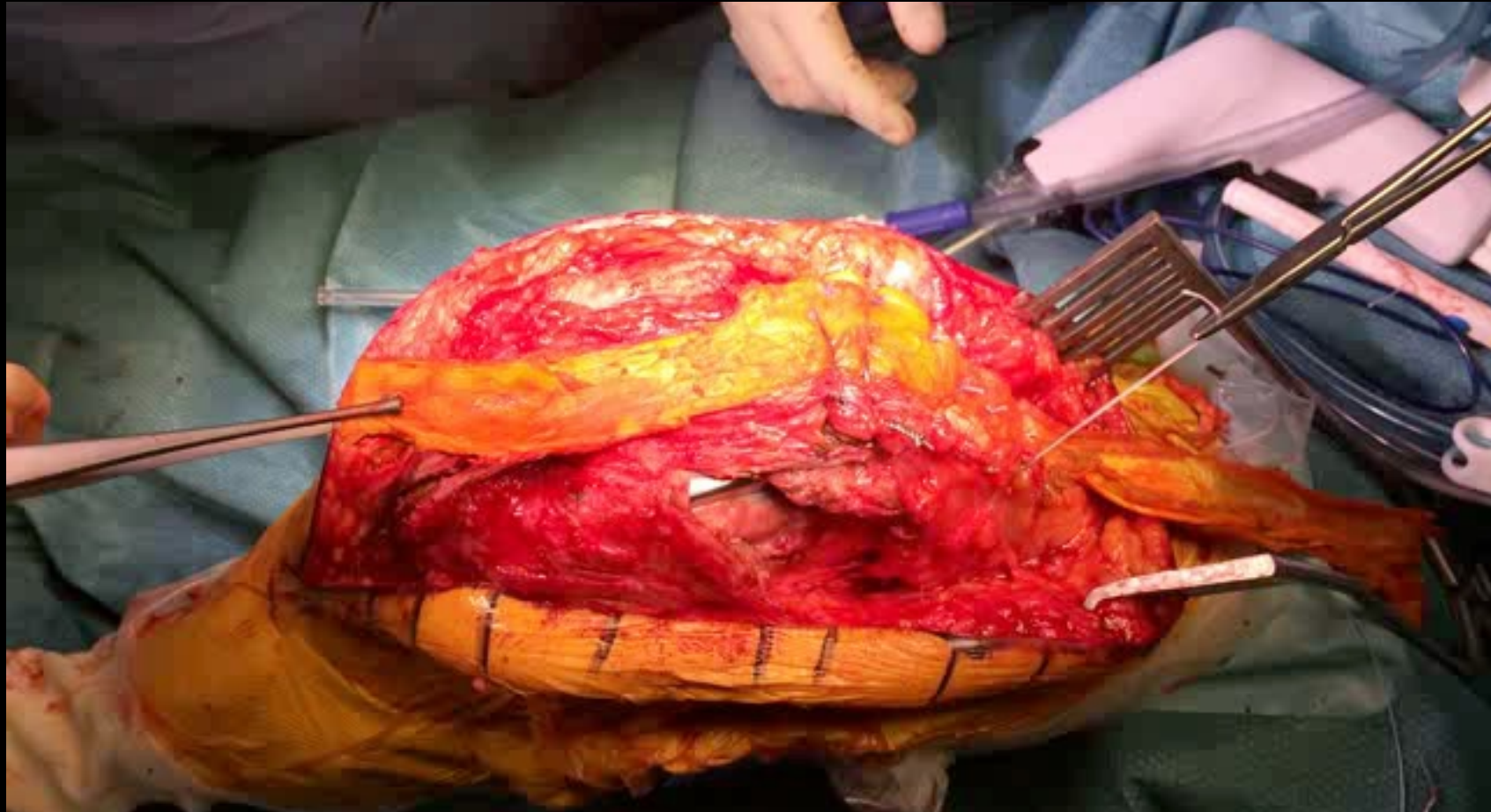

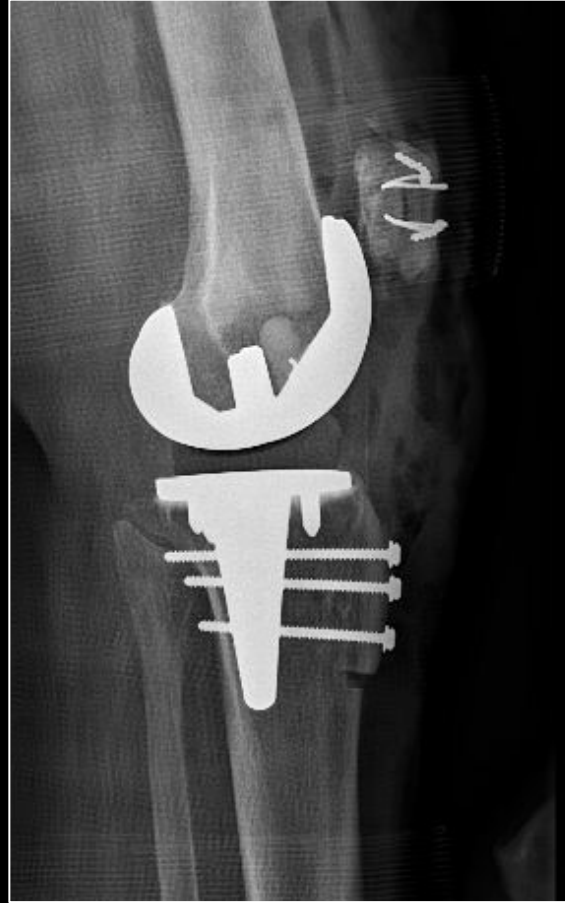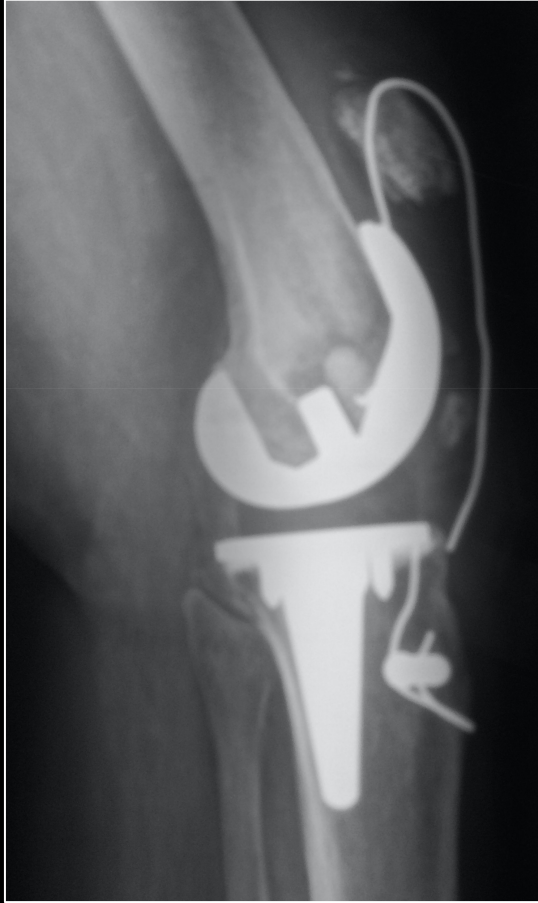Surgical procedure

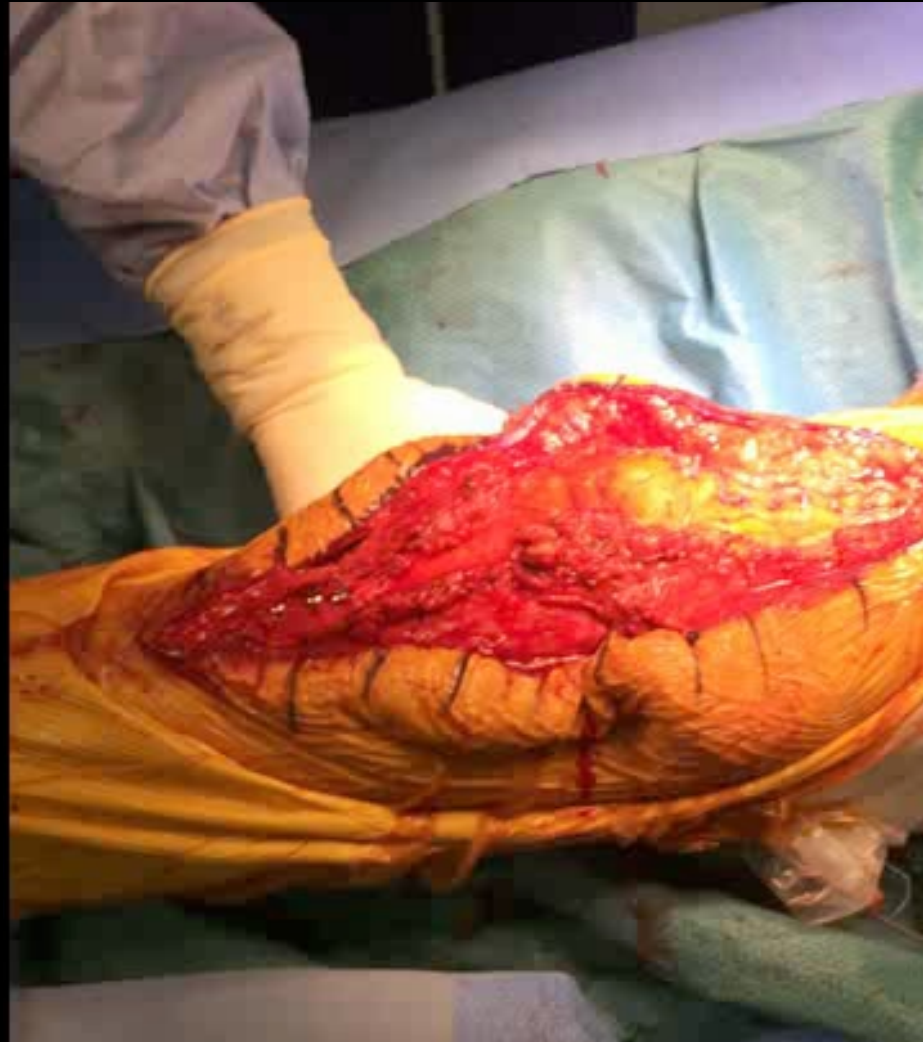1. Graft : extensor mechanism allograft
2. Preparation of the allograft
3. Preparation of the extensor mechanism
4. **Graft fixation**

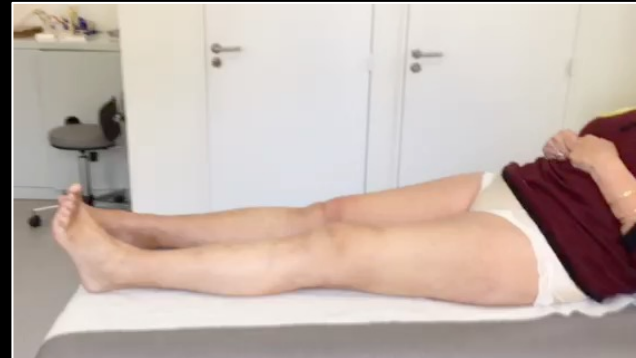
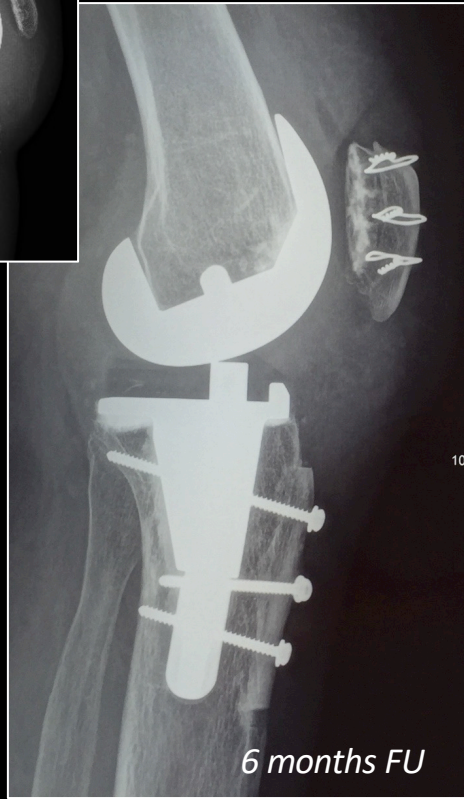
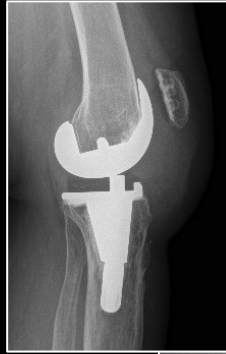











Thks for your attention

sebastien.lustig@gmail.com

